



**PATIENT**

Charlie Fraser

**SPECIES**

Canine

**BREED**

Chihuahua

**SEX**

Male Neutered

**AGE**

3 years

**WEIGHT**

15lbs

**INTERPRETED BY**

Maggie Machen  
Lamy, DVM  
DACVIM (Cardiology)

**IMAGING PERFORMED BY**

Eduardo Rodriguez  
III, RCS

**HOSPITAL NAME**

Norfolk County  
Veterinary Service

**REFERRING VET**

Dr. Ilovich

**INVOICE**

29803

**DATE**

3/23/23

**PRESENTING CLINICAL SIGNS**

History: Recheck echo. History chronic valvular disease -B1. Charlie is doing well at home with no clinical issues. BP: 130, 132, 134mmHg.

-Pertinent previous echo findings (9/1/22 MML): LA 1.9 cm, LA:Ao 1.5, LV 2.6, mild LAE, mild MR, trace TR (2.3 m/s).

**ECHOCARDIOGRAM FINDINGS**

2D, m-mode, color flow and Doppler imaging is available.

**Left ventricle:** The LV diameter is normal with adequate myocardial function. LV wall thicknesses are normal.

**Left atrium:** The left atrium is normal.

**Mitral valve:** The mitral valve is diffusely thickened with minimal prolapse into the left atrial lumen. Mild eccentric mitral regurgitation with a normal velocity.

**Aortic valve/aorta:** The aortic valve is normal in morphology and mobility. Normal aortic outflow velocity; laminar flow. No aortic insufficiency.

**Right ventricle:** Normal right ventricular diameter and morphology indicating no overt evidence of pulmonary arterial hypertension.

**Right atrium:** Normal RA dimension.

**Tricuspid valve:** The tricuspid valve appears normal with trace tricuspid regurgitation. Mildly elevated velocity.

**Pulmonic valve/pulmonary artery:** The pulmonic valve is normal in morphology and mobility. No pulmonic insufficiency. Normal RVOT velocity; laminar flow.

**Pericardium/other:** No pericardial or pleural effusion noted. No obvious cardiac masses.

**Heart rhythm:** ECG reveals a sinus rhythm with an average HR of 130bpm.

**2-Dimensional Measurements**

Ao diam (cm)	1.3
LA diam (cm)	1.6
LA:Ao (Swe)	1.3
IVS thickness (cm)	0.6
LVID diastole (cm)	2.4
PW thickness (cm)	0.6
LVID systole (cm)	1.0
FS (%)	57

**Doppler Measurements**

PV Vmax (m/s)	1.0
AoV Vmax (m/s)	1.9
MR Vmax (m/s)	4.9
TR Vmax (m/s)	3.0
TR PG (mmHg)	36

**INTERPRETATION OF THE FINDINGS**

Compared to the prior study, findings are similar. The left heart dimensions do show significant progressive dilation and the MR is stable. Mild pulmonary hypertension is noted, which is of unknown significance in an asymptomatic dog. No additional issues are identified.

Given these findings, no medications are indicated. Continued assessment of progression in the future will help predict long term prognosis, which is highly variable at this stage (B1).

**RECOMMENDATIONS**

- No cardiac medications are clearly indicated.



**PATIENT**

Charlie Fraser

**SPECIES**

Canine

**BREED**

Chihuahua

**SEX**

Male Neutered

**AGE**

3 years

**WEIGHT**

15lbs

**INTERPRETED BY**

Maggie Machen Lamy, DVM  
 DACVIM (Cardiology)

**IMAGING PERFORMED BY**

Eduardo Rodriguez III, RCS

**HOSPITAL NAME**

Norfolk County Veterinary Service

**REFERRING VET**

Dr. Ilovich

**INVOICE**

29803

**DATE**

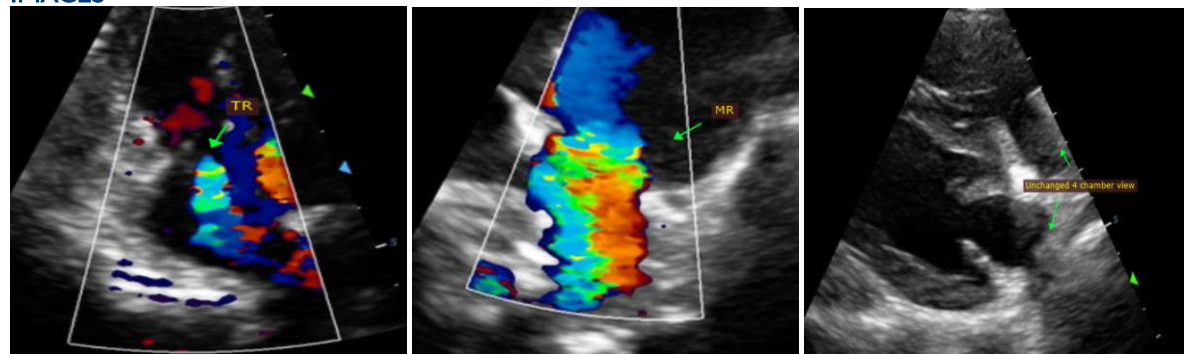
3/23/23

- Omega fatty acid supplementation and mild salt restriction may be of some long-term benefit.
- Anesthetic risk is considered mild if needed. Cardiac protective drug choices (opioid/benzodiazepine premedication, propofol or alfaxalone induction, isoflurane gas) are recommended. Pre-oxygenate for 5-10 minutes prior to induction. Monitor for arrhythmias, hypotension, and hypoxia both intra and post-operatively and intervene as necessary. Mild IV fluid restriction is recommended to avoid fluid overload. Avoid heart rate stimulating drugs such as atropine unless clinically indicated.
- Monitor for development of a cough, labored breathing, exercise intolerance or collapse episodes.

**PLAN**

- Recommend conservative monitoring with a recheck echocardiogram in 6-12 months, sooner if any development of clinical signs.

**IMAGES**



The information and recommendations provided are based on the images presented by the referring veterinarian. No evaluation can be communicated regarding pathology that was not visible in the image/video clips provided.

Thank you for this referral. This report was generated using transcription software, and minor dictation errors may be present. If the clinical or image interpretation does not parallel your findings or if I can be of any further assistance, please contact me.

**Maggie Machen Lamy, DVM**  
 Diplomate of the American College of Veterinary Internal Medicine (Cardiology)  
 info@sonopath.com

**Echocardiogram performed by:** Pamela Harrigan, RDCS  
 Pet Animal Ultrasound Service ([4paus.com](http://4paus.com))